

Kidney histology

George Liapis, MD, Dept. of Pathology,
Laiko General Hospital, University of Athens

Structure and function of the kidney

- Main function: Maintenance of water and electrolyte homeostasis
- 1/5 of blood supply is directed to the kidney. The total blood volume of the body is circulated through the kidneys about 300 times each day.
- 1.000.000 – 1.500.000 nephrons, with a broad range between individuals, related to birth weight
- Average weight: 150gr. Average size in adults 10-12 cm. **Participation of 26 cell types in the structure!**

A catalogue of differentiated cells of the mature kidney

				Wolffian duct	
Nephron epithelia	Endothelia	Stroma	Smooth muscle	Ureteric bud	Urogenital sinus
Podocyte	Glomerular	Cortical	Mesangial	Principal	Bladder
Parietal	Peritubular	Medullary	Vascular	α-Intercalated	Urethra
Proximal	?Large vessel		Ureteric	β-Intercalated	
S1, S2, S3			Detrusor	Inner medullary	
Thin descending				Pelvis	
Thin ascending				Ureter	
Thick ascending					
Cortical					
Medullary					
Macula densa					
Distal tubule					

Al-Awqati Q., Oliver J.A. Kidney International, Vol. 61 (2002), pp. 387–395

Embryology of the kidney

Double origin

- Ureteral bud (metanephric duct)
  - Collecting duct
  - Calyces
  - Pelvis
  - Ureter

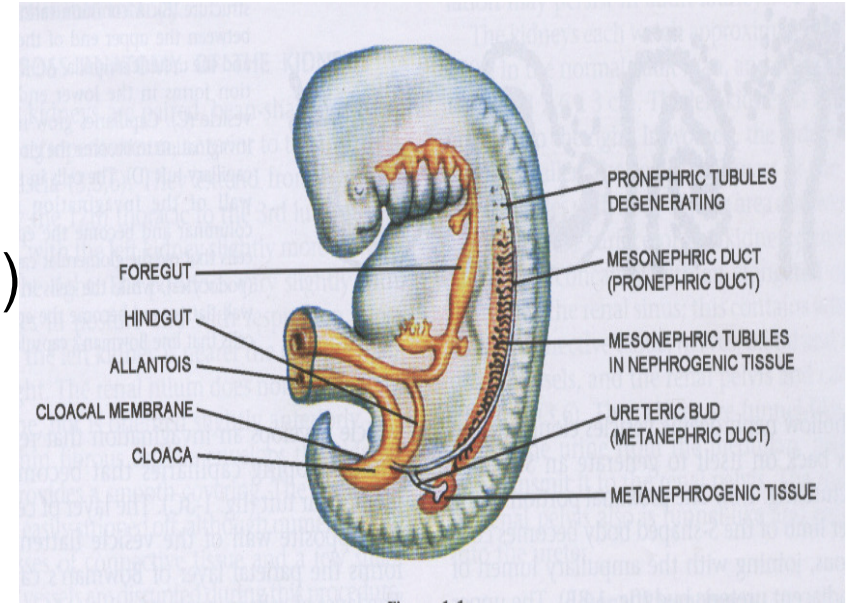

- Metanephric blastema (nephron and all the others renal structures)

Vascular supply

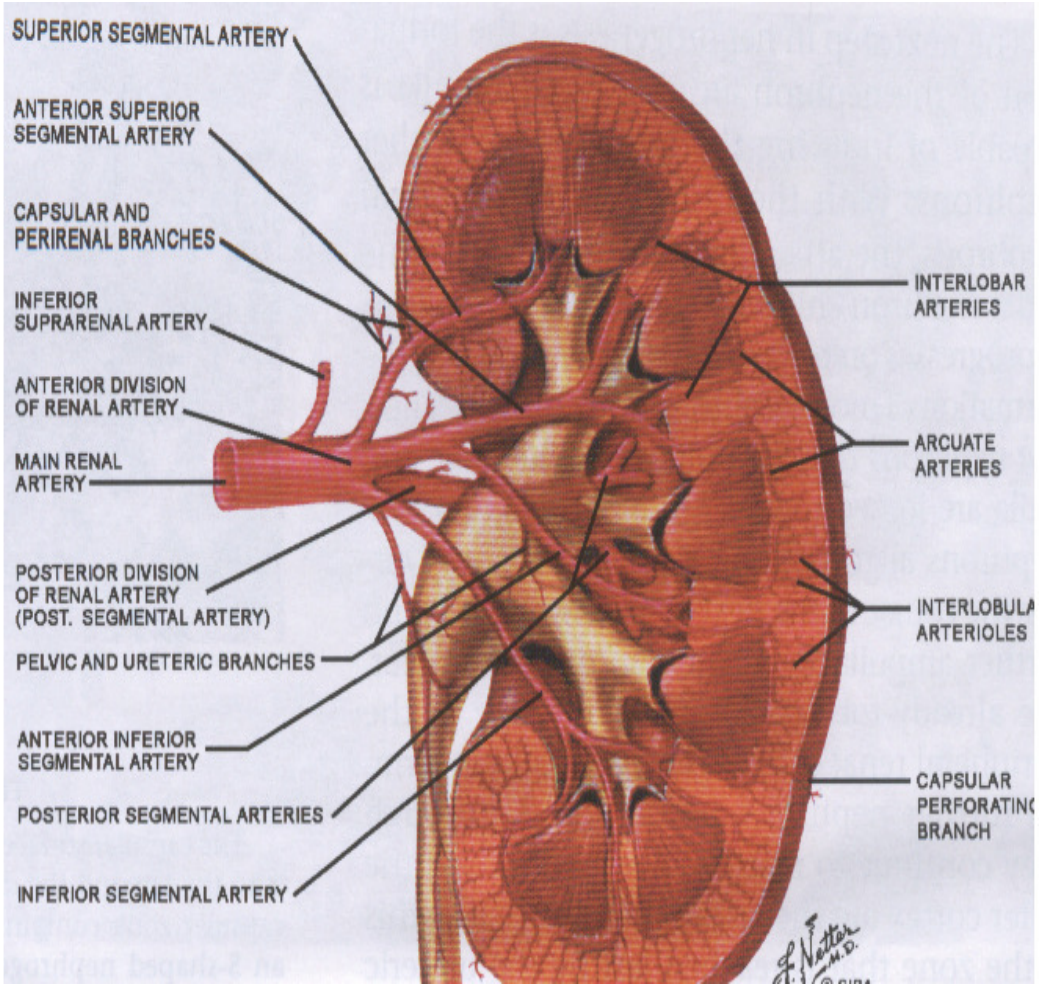

- Renal artery
- Two branches
- Interlobar arteries
- Arcuate arteries
- Interlobular arteries
- Afferent arterioles

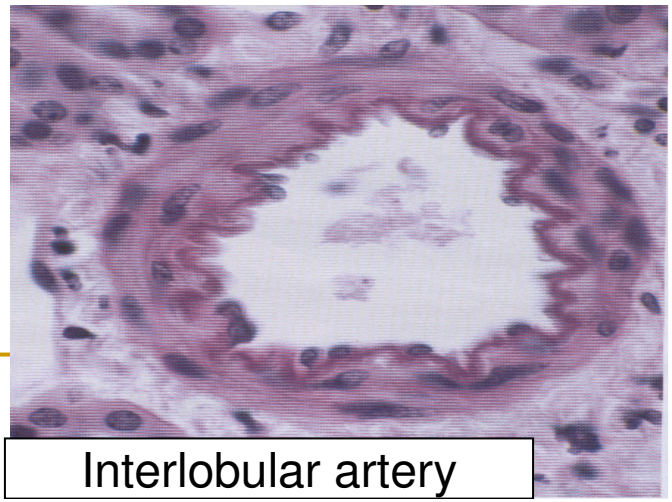

Interlobular artery

Kidney anatomy/histology

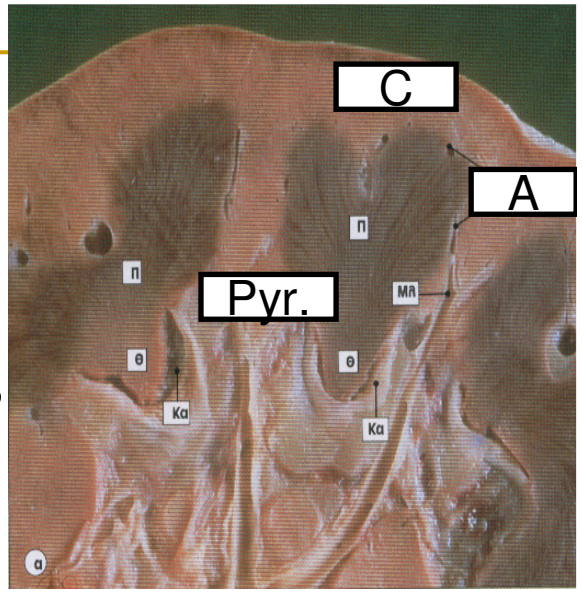

Anatomy: Cortex – Medulla – Pelvis

segment of Cortex + pyramid = renal lobe (10-18 lobes)

The basic anatomical structure

Histology - Four compartments

- Glomeruli
- Tubules
- Vessels
- Interstitium

→ Nephron

The basic functional structure

Nephron

Nephron, the basic functional structure of the kidney

- Renal corpuscle
  - Glomerulus
  - Bowman's Capsule
- Renal tubule – a long folded structure (It is up to 55 mm long in humans and extends from Bowman's capsule to its junction with a collecting duct)
  - Proximal convoluted tubule
  - Loop of Henle (pars recta, thin descending limb, thin ascending limb, thick ascending limb)
  - Distal convoluted tubule
  - Collecting tubule (consisted of principal and intercalated cells)

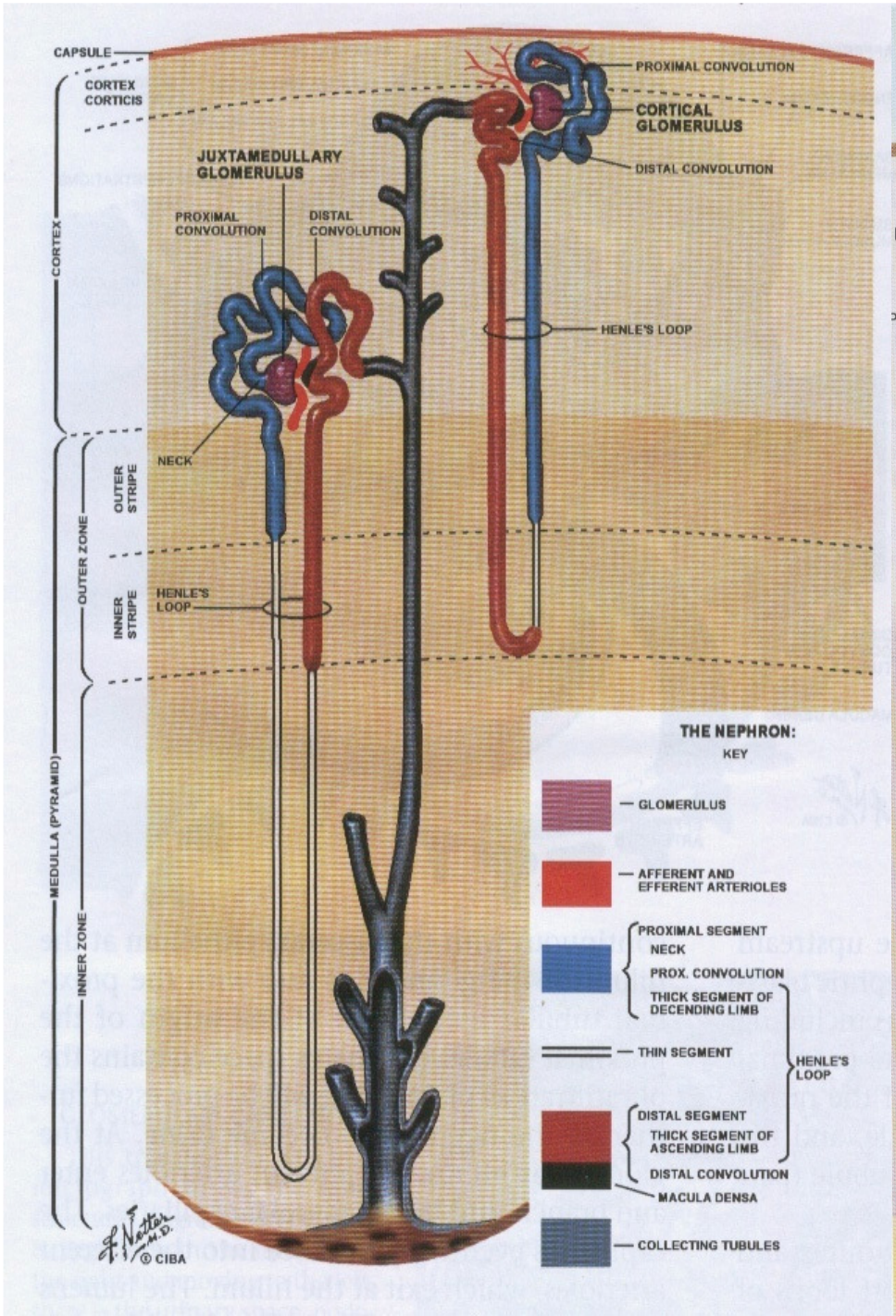
CAPSULE
CORTEX CORTICIS
CORTEX
OUTER ZONE
INNER ZONE
MEDULLA (PYRAMID)
OUTER STRIPE
INNER STRIPE
JUXTAMEDULLARY GLOMERULUS
PROXIMAL CONVOLUTION
DISTAL CONVOLUTION
NECK
HENLE'S LOOP
PROXIMAL CONVOLUTION
CORTICAL GLOMERULUS
DISTAL CONVOLUTION
HENLE'S LOOP
THE NEPHRON:
KEY
GLOMERULUS
AFFERENT AND EFFERENT ARTERIOLES
PROXIMAL SEGMENT
NECK
PROX. CONVOLUTION
THICK SEGMENT OF DECENDING LIMB
THIN SEGMENT
HENLE'S LOOP
DISTAL SEGMENT
THICK SEGMENT OF ASCENDING LIMB
DISTAL CONVOLUTION
MACULA DENSA
COLLECTING TUBULES
F. Netter M.D.
© CIBA

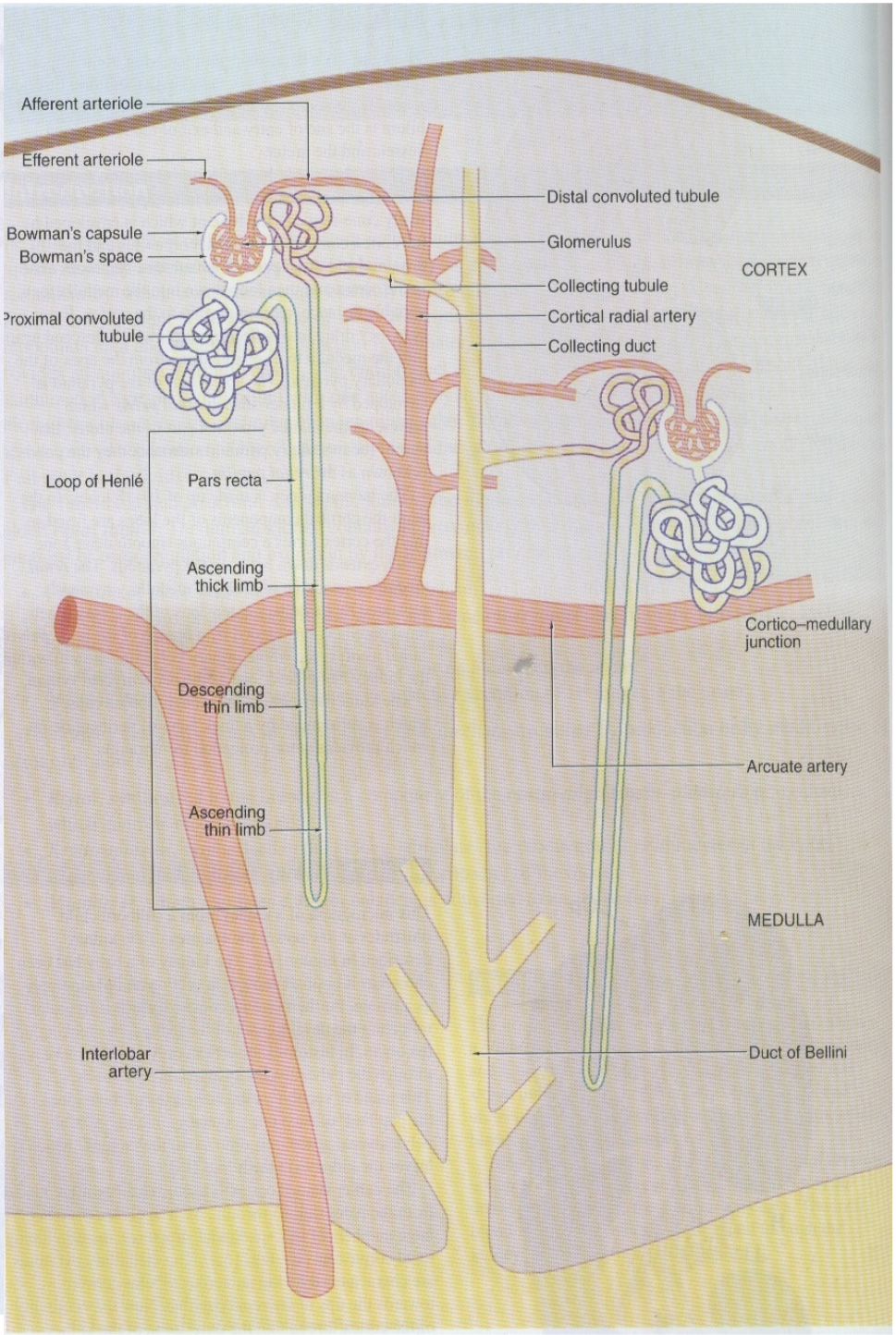
Afferent arteriole
Efferent arteriole
Bowman's capsule
Bowman's space
Proximal convoluted tubule
Loop of Henlé
Pars recta
Ascending thick limb
Descending thin limb
Ascending thin limb
Interlobar artery
Distal convoluted tubule
Glomerulus
Collecting tubule
Cortical radial artery
Collecting duct
CORTEX
Cortico–medullary junction
Arcuate artery
MEDULLA
Duct of Bellini

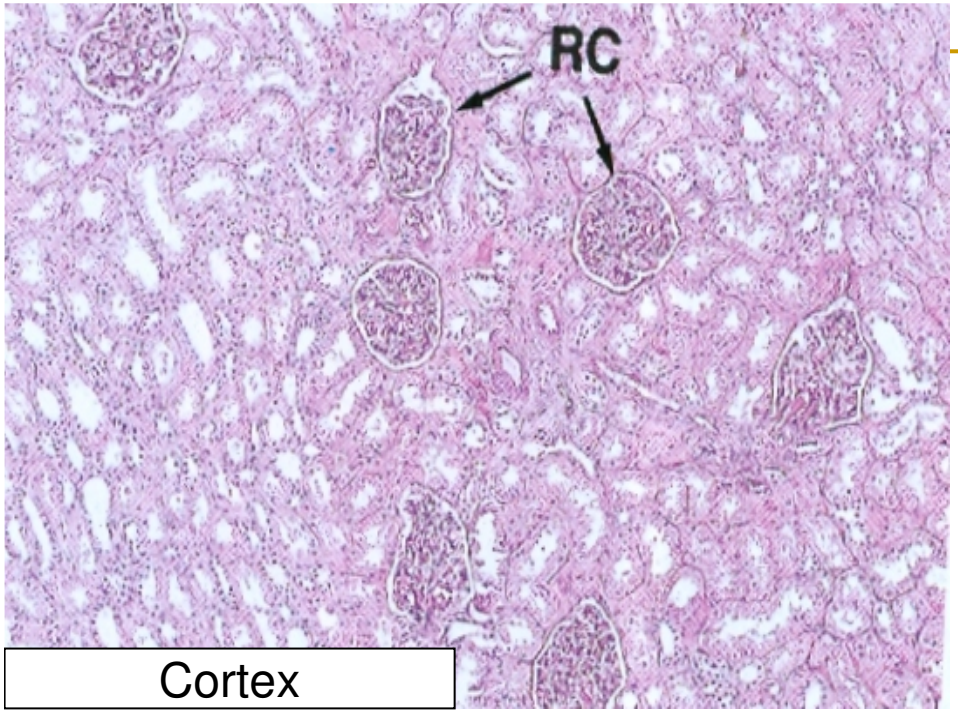

Cortex

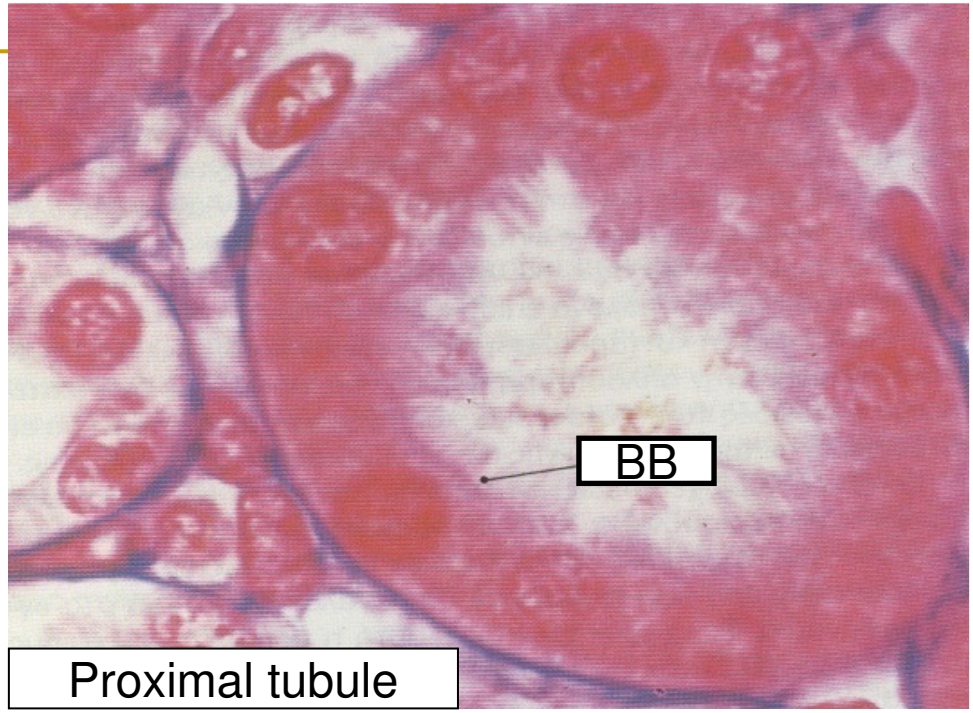

Proximal tubule

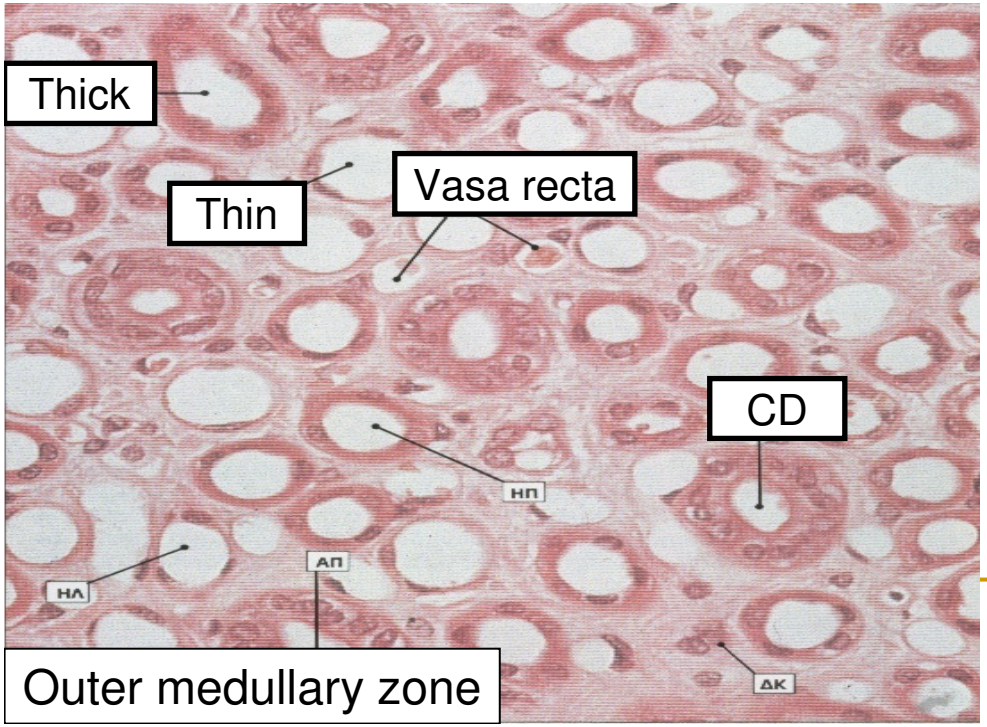

Outer medullary zone

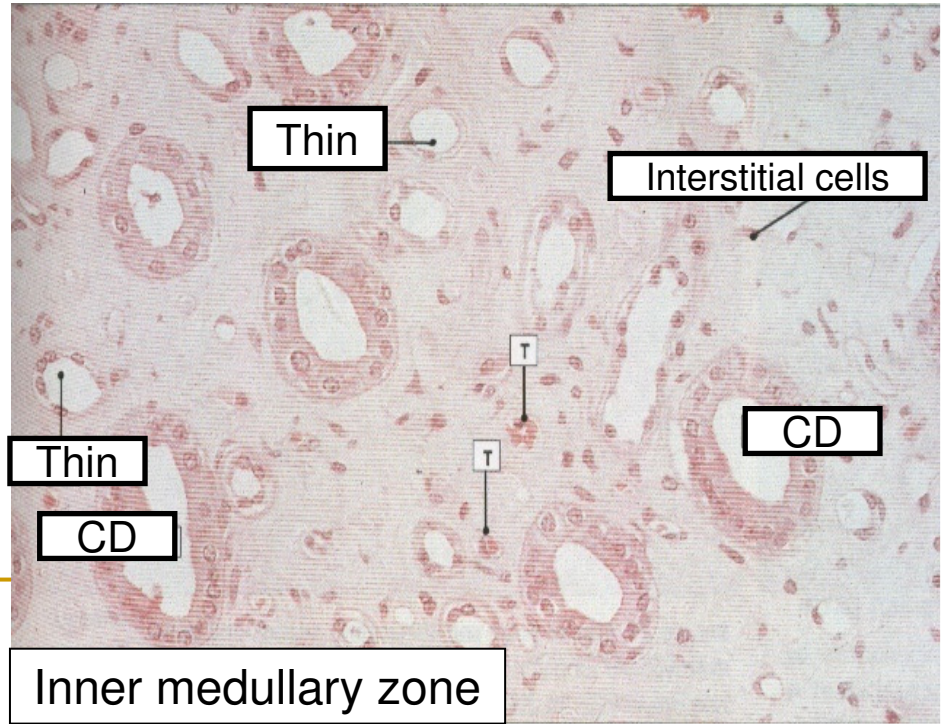

Inner medullary zone

Biopsy cores

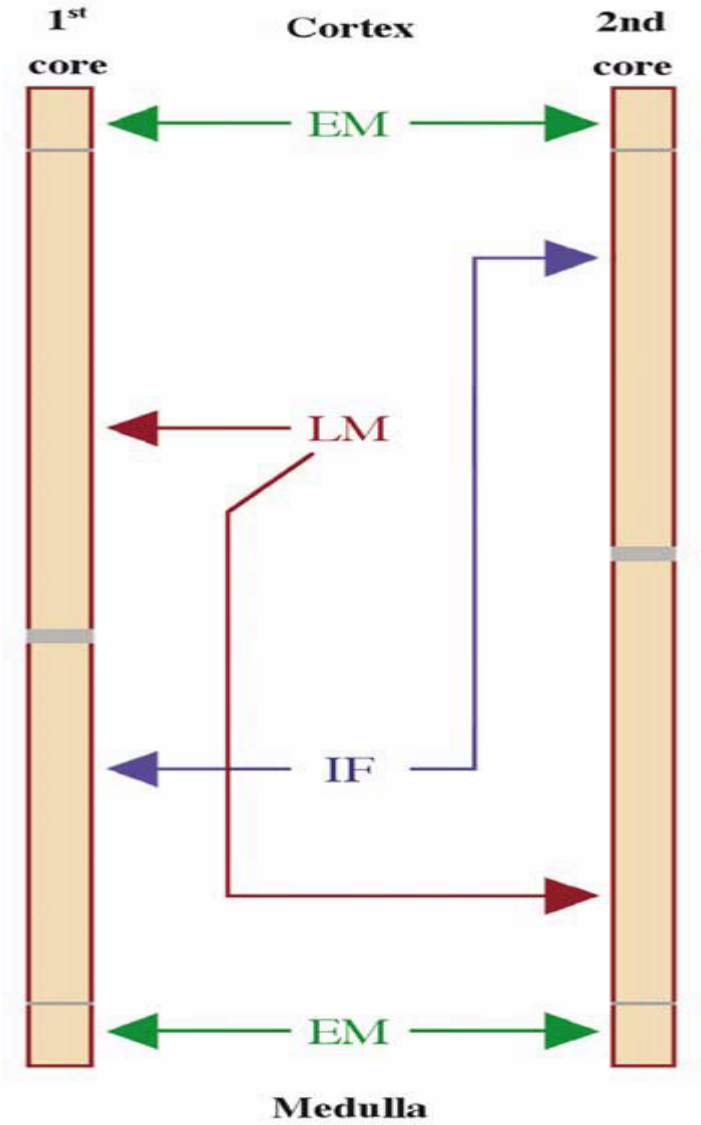

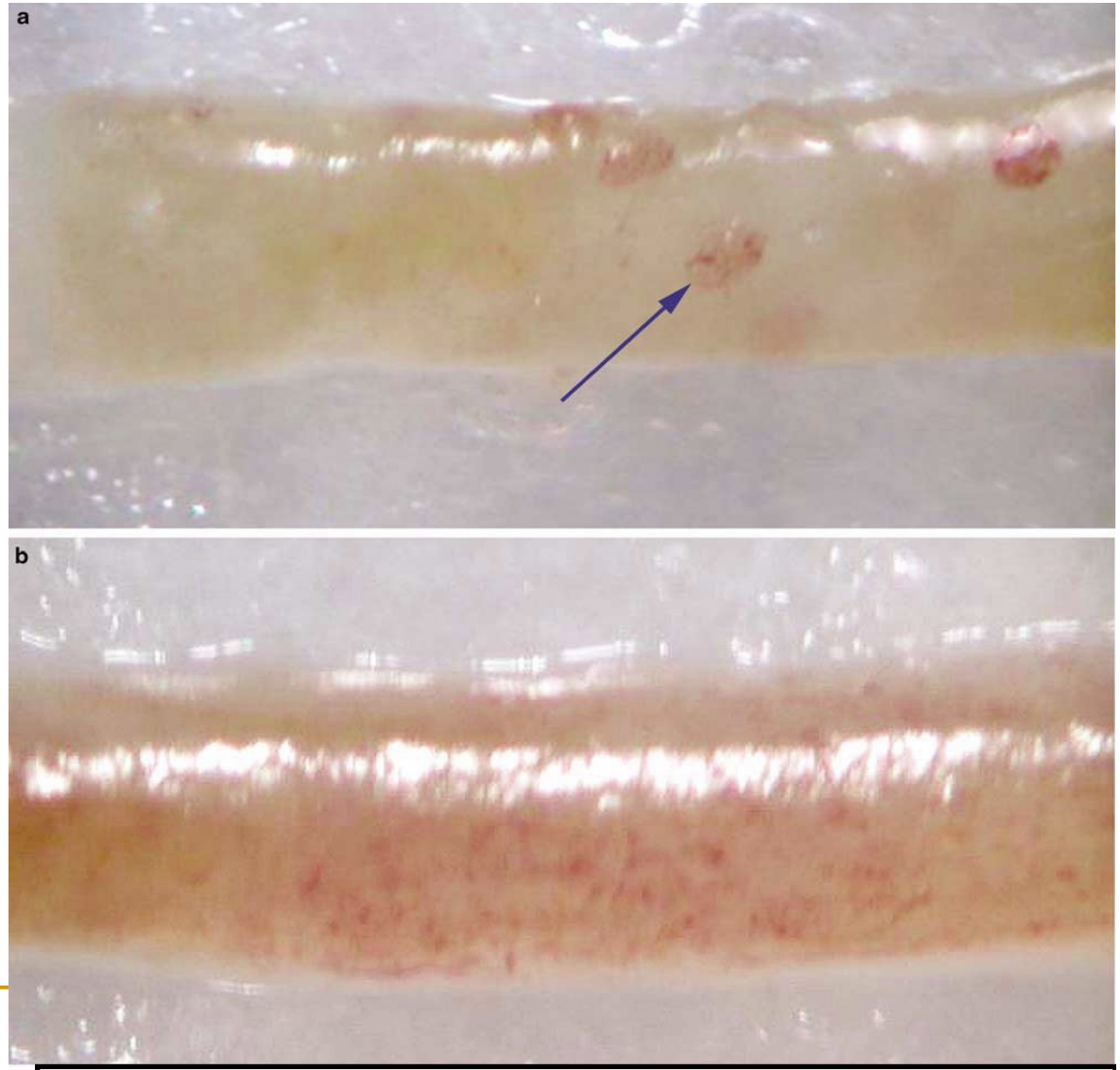

Walker PD. et al. Mod Pathol. 2004 Dec;17(12):1555-63.

Glomerulus, cell types

Spherical to ellipsoid cluster of capillaries supported by mesangium which is the glomerular matrix

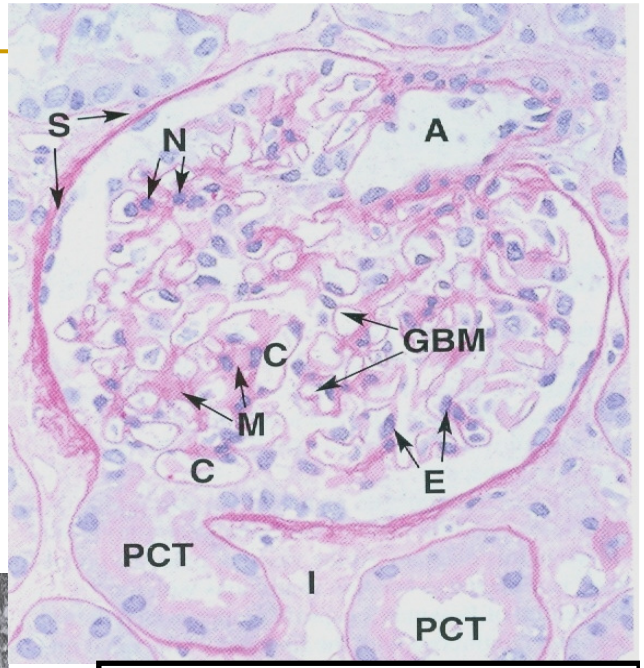

Wheater's histology

- Mesangial cells
- Endothelial cells
- Podocytes
- Parietal cells

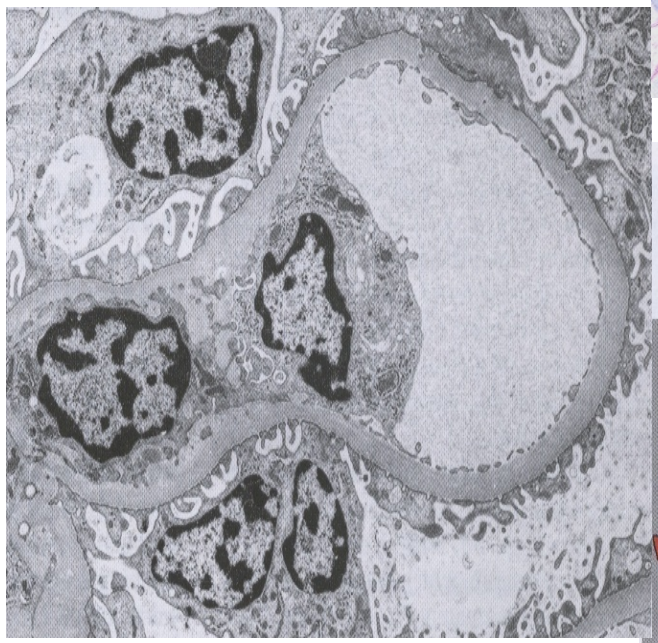



Glomerulus mean diameter: 200 µm
Juxtamedullary glomeruli and glomeruli of solitary kidney are larger

The glomerular "barrier"

- Capillary endothelium with fenestrations (70-100nm in diameter) without diaphragms, negative charged due to podocalyxin
- Glomerular basement membrane (240-340nm thickness) divided in lamina rara interna, lamina densa, lamina rara externa (both laminae rarae electron lucent, negatively charged)
- Podocytes with primary and secondary foot processes

Permeability depends on electrical charge, molecular size and configuration

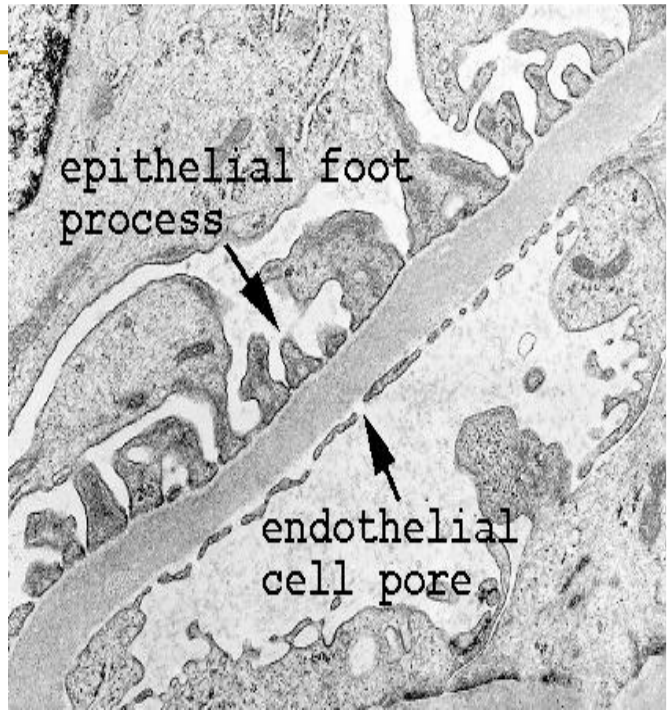

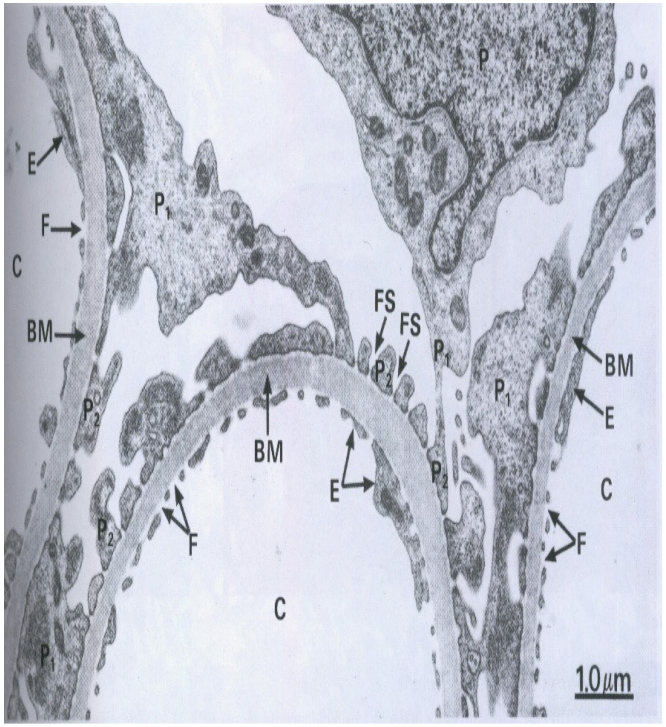

Part of tubule	Type of epithelium	Special features	Functional significance
Proximal convoluted tubule	Simple cuboidal	Microvilli (brush border) Extensive basolateral interdigitations Plentiful mitochondria	Facilitated diffusion glucose, amino acids Na^+ pump Energy for active transport
Pars recta of proximal tubule	Simple cuboidal	Microvilli (brush border) No basolateral interdigitations	Secretion of organic acids
Thin descending/ascending limbs	Simple squamous	No basolateral interdigitations or microvilli Mitochondria scanty	No active transport Low energy requirement
Thick ascending limb	Simple cuboidal	Microvilli absent Extensive basolateral interdigitations	No facilitated diffusion Active transport of Na^+
Distal convoluted tubule (DCT)	Simple cuboidal	Extensive basolateral interdigitations Mitochondria plentiful	Active transport of Na^+ Energy for active transport
Collecting tubule	Simple cuboidal	Principal cells Intercalated cells DCT cells Collecting tubule cells	Na^+ reabsorption, ADH-dependent water reabsorption, K^+ secretion Acid–base balance, K^+ reabsorption Active transport of Na^+
Cortical collecting duct	Simple columnar	Principal cells Intercalated cells	Na^+ reabsorption, ADH-dependent water reabsorption, K^+ secretion Acid–base balance, K^+ reabsorption
Medullary collecting duct	Simple columnar	Mainly principal cells	ADH-dependent water reabsorption

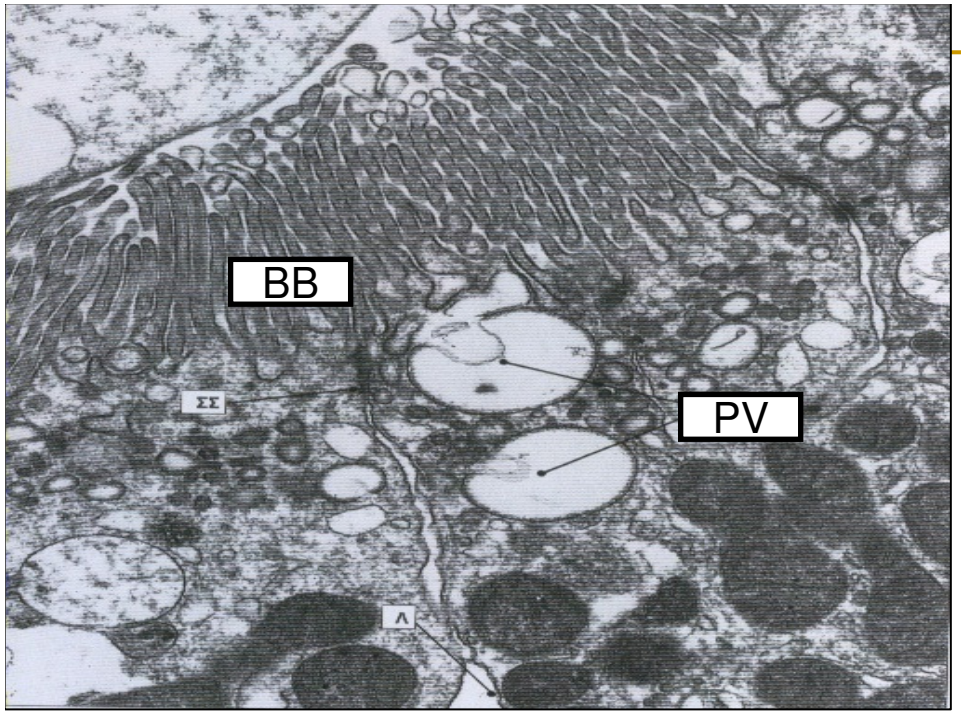

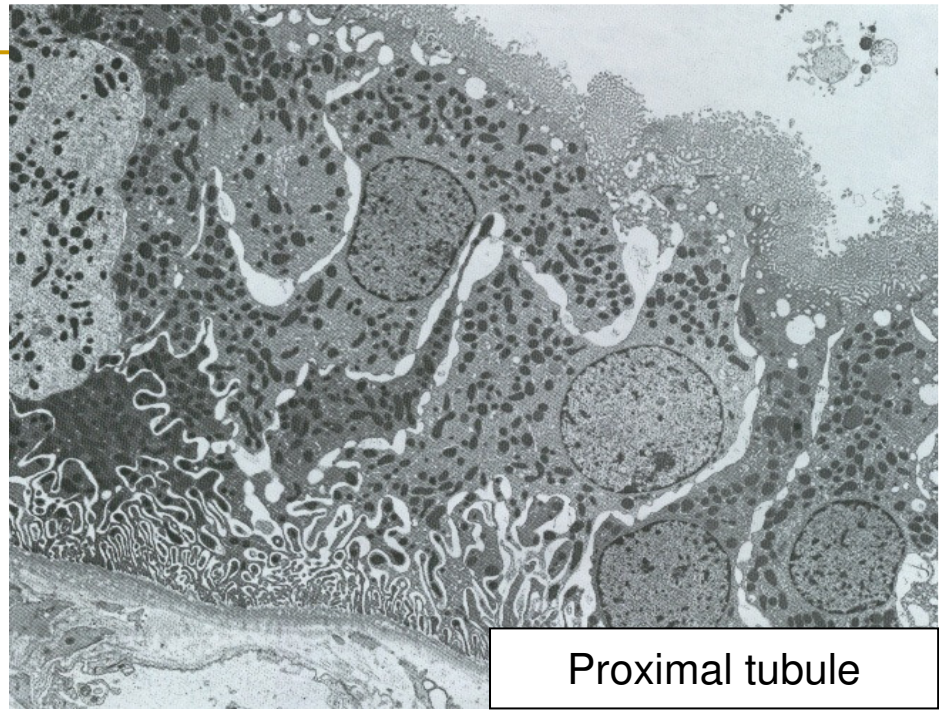

Proximal tubule

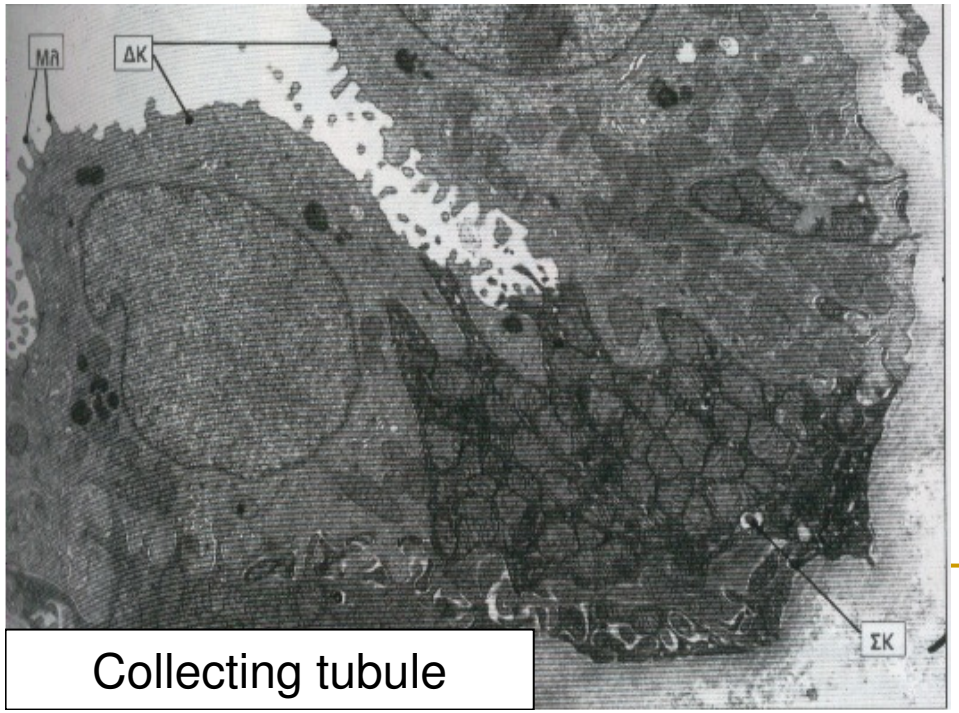

Collecting tubule

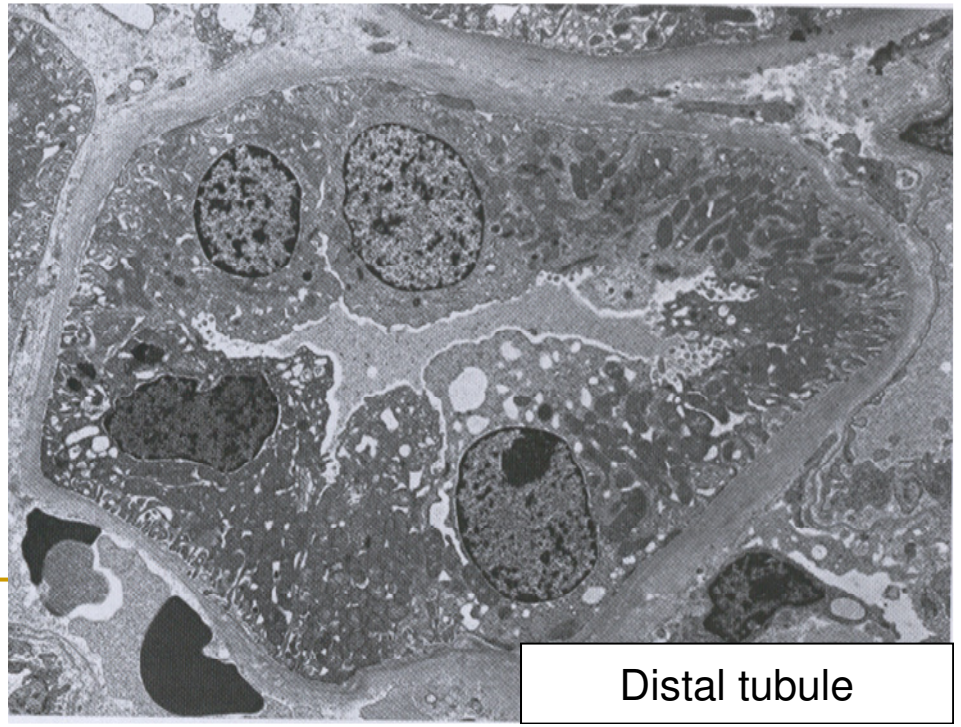

Distal tubule

Renal papilla

- The apex of renal pyramid forms the renal papilla which contains ducts of Bellini (the largest of the collecting ducts)

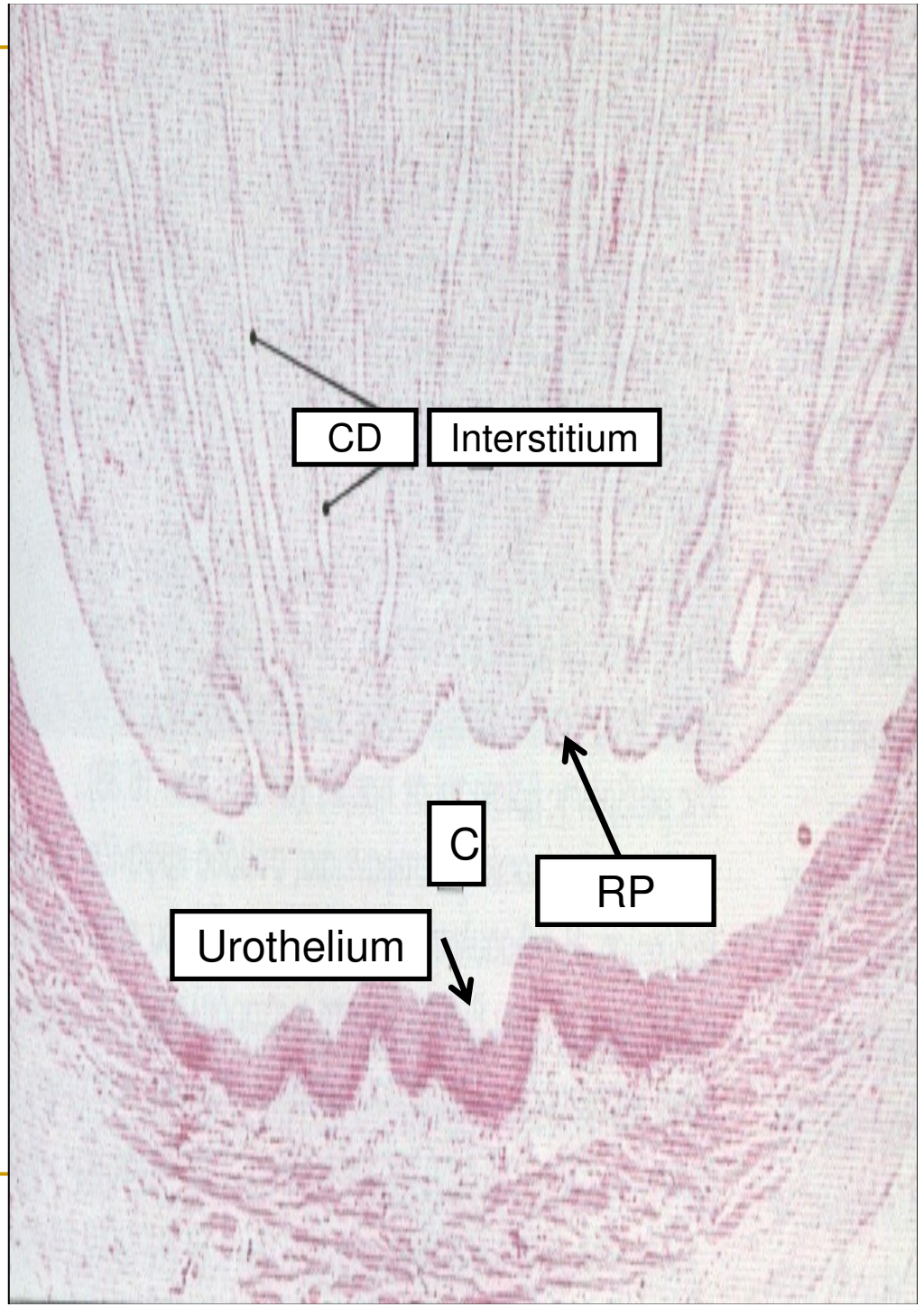

Classification of diseases/types

Primary involvement - localization

- Glomerular (the commonest, Glomerulonephritis- acute/chronic)
- Tubulointerstitial (Interstitial nephritis)
- Vascular (Vasculitis, Arterionephrosclerosis)

Aetiopathogenesis

- GN with immunocomplexes
- Nephropathies without immunocomplexes

Histology patterns of injury / description

- MPGN
- Nodular glomerulosclerosis etc

Diseases since advanced affect all the kidney compartments

Common histological patterns of glomerular injury

A limited number of ways to respond to injury

- No abnormalities by light microscopy
- Thick capillary walls without hypercellularity or mesangial expansion
- Thick walls with mesangial expansion but little or no hypercellularity
- Focal segmental glomerulosclerosis without hypercellularity
- Mesangial or endocapillary hypercellularity
- Extracapillary hypercellularity
- Membranoproliferative, lobular or nodular pattern
- Advanced diffuse global glomerular sclerosis

Histology patterns and diseases: variation and discrepancies

- Renal disease is manifested by a limited number of symptoms which are often grouped in clinical syndromes

  (i.e., asymptomatic renal failure, nephrotic syndrome, etc)

- A few histological patterns of injury, many diseases!
- One histological pattern of kidney injury can be encountered in several different diseases. It is not disease specific (FSGS).
- One disease can display several histological patterns. It is not pattern specific (SLE, IgA).
- A certain immunological disease (e.g SLE) can result in different "faces" and cause different diseases/grades/stages/classes in kidneys
- A certain infectious agent can cause different patterns and diseases (post infectious GN, MPGN).

SLE, the prototypical example of pattern complexity

FSGS

May display several patterns often in combination

Sometimes, non specific pattern of end stage glomerular injury caused by other etiologies/diseases

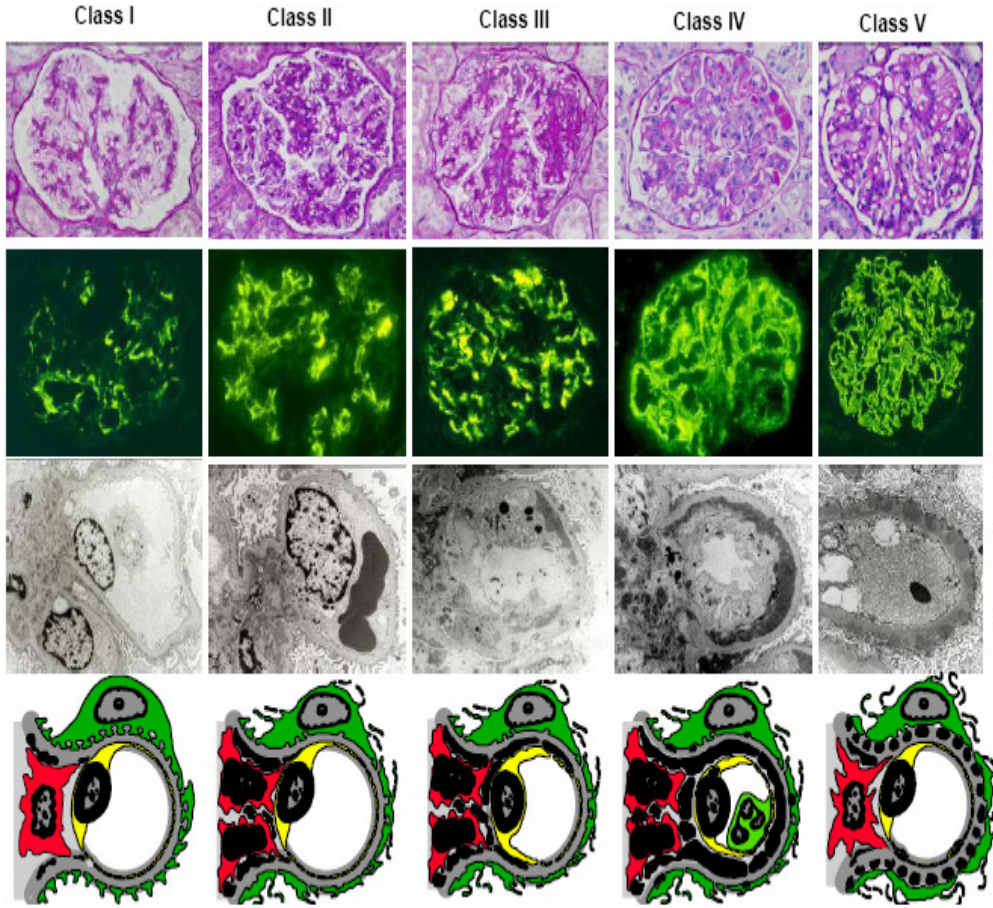

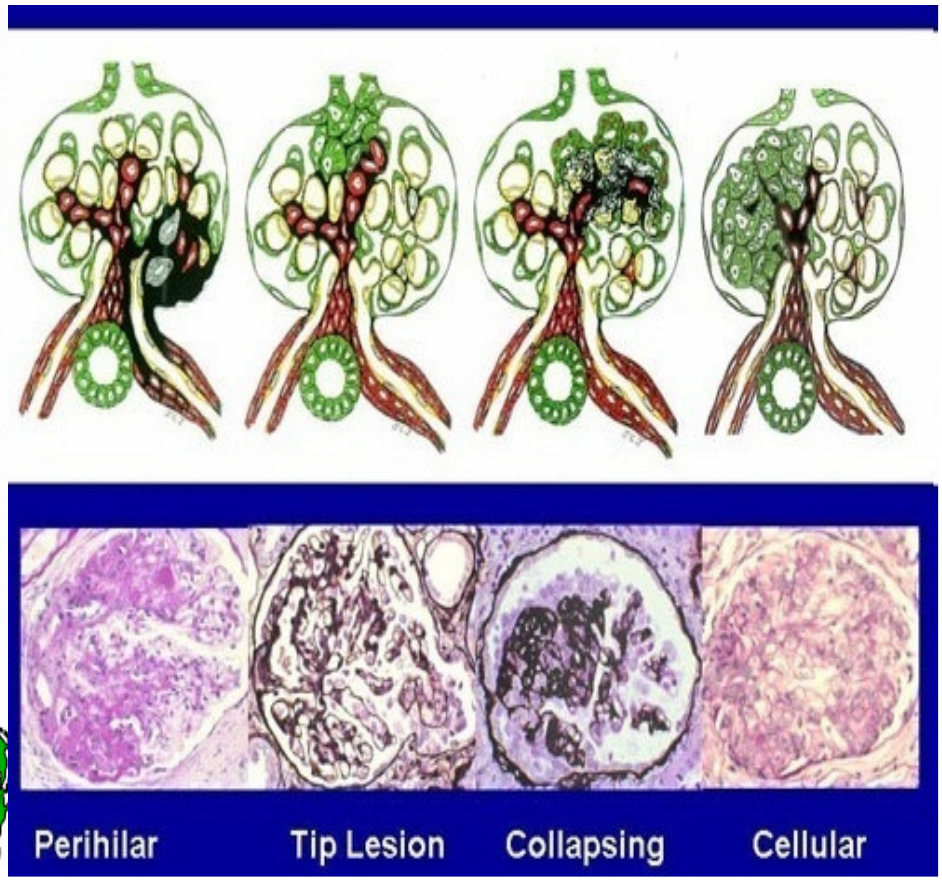

ESRD – Common outcome of different diseases

- Non specific type of severe kidney injury including segmental or global glom/sclerosis, TA and IF, usually accompanied by interstititial inflammation
- The most common kidney diseases in the Western world that result in ESRD are:
  - Diabetes Mellitus
  - Hypertension
  - Glomerulonephritis
  - Interstitial nephritis
  - Hereditary conditions (ADPKD)
  - Malignancy

70%

10%

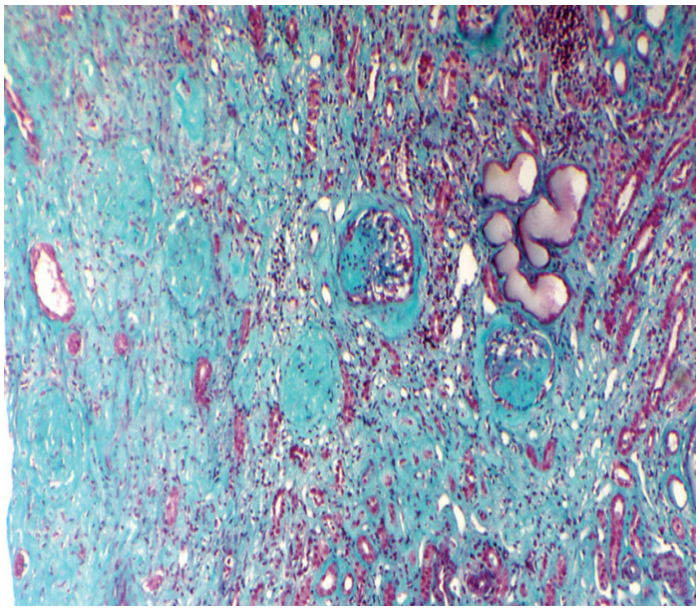

- 11% of U.S.A adult population has been estimated have CKD

Concluding remarks

Renal morphology is complex and several alterations occur during diseases
These alterations are dependant on stage of the disease
They may be common for different diseases

What is the SAME from a morphological point of view may be quite different from the point of view of the "PROTEOMIC PROFILE", generated from a well defined (possibly isolated by LCM) part of tissue

A better understanding and especially classification of a renal disease will require the collaboration of pathologists and biochemists, in order to converge histology images with proteomics data. If achieved, this will lead to better prognostic and diagnostic markers and will contribute to "personalized medicine"

Contact Working Groups Executive Management

Eurokup

Home :: European Kidney and Urine P

working groups

Clinicians, pathologists, molecular biologists in association with the biochemistry and omics technology in the same circle. Target the patient and the disease

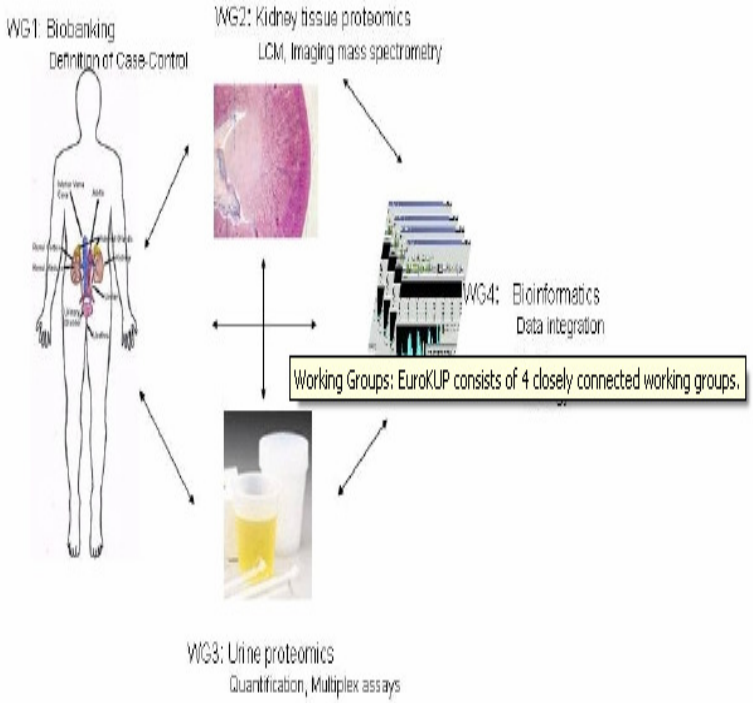



Thank you very much!